

4-21-2025

Anisakid nematodes in Black Sea harbour porpoise (*Phocoena phocoena* ssp. *relicta*) from the Turkish Western Black Sea: with notes about association with body length and stomach content

ERDEM DANYER

İŞİL AYTEMİZ DANYER

ARDA MEHMET TONAY

AYHAN DEDE

HAYRETTİN AKKAYA

Follow this and additional works at: <https://journals.tubitak.gov.tr/veterinary>

Recommended Citation

DANYER, ERDEM; AYTEMİZ DANYER, İŞİL; TONAY, ARDA MEHMET; DEDE, AYHAN; and AKKAYA, HAYRETTİN (2025) "Anisakid nematodes in Black Sea harbour porpoise (*Phocoena phocoena* ssp. *relicta*) from the Turkish Western Black Sea: with notes about association with body length and stomach content," *Turkish Journal of Veterinary & Animal Sciences*: Vol. 49: No. 2, Article 7. <https://doi.org/10.55730/1300-0128.4374>

Available at: <https://journals.tubitak.gov.tr/veterinary/vol49/iss2/7>



This work is licensed under a [Creative Commons Attribution 4.0 International License](https://creativecommons.org/licenses/by/4.0/).

This Research Article is brought to you for free and open access by TÜBİTAK Academic Journals. It has been accepted for inclusion in Turkish Journal of Veterinary & Animal Sciences by an authorized editor of TÜBİTAK Academic Journals. For more information, please contact academic.publications@tubitak.gov.tr.

Anisakid nematodes in Black Sea harbour porpoise (*Phocoena phocoena* ssp. *relicta*) from the Turkish Western Black Sea: with notes about association with body length and stomach content

Erdem DANYER^{1*} , Işıl AYTEMİZ DANYER¹ , Arda M. TONAY^{1,2} , Ayhan DEDE^{1,2} , Hayrettin AKKAYA³ 

¹Turkish Marine Research Foundation (TUDAV), İstanbul, Türkiye

²Department of Marine Biology, Faculty of Aquatic Sciences, İstanbul University, İstanbul, Türkiye

³Department of Nutrition and Dietetics, Faculty of Health Sciences, İstanbul Sabahattin Zaim University, İstanbul, Türkiye

Received: 13.12.2023

Accepted/Published Online: 30.01.2025

Final Version: 21.04.2025

Abstract: Parasites are naturally present in the natural gastrointestinal fauna of marine mammals without necessarily causing any pathology. However, under various stress conditions, parasites can cause pathological disorders in the gastrointestinal system. There is insufficient information on parasite fauna of mammals living in the Black Sea waters off the Turkish coast. This study examined the stomach contents of bycaught and stranded harbour porpoises collected between 2002 and 2003 along the Turkish coast of the western Black Sea for parasitic presence. In a previous stomach content study, 450 nematode fragments (including 232 intact specimens) were occasionally collected from 33 harbour porpoises (27 females and 6 males) and preserved in 70% ethanol at room temperature. Nematodes were detected in 78.5% of the examined harbour porpoise stomachs. The nematodes were identified as *Contracaecum* spp. and *Hysterothylacium* spp. in their larval forms, as well as adult specimens of the family Anisakidae (Railliet & Henry, 1912). Understanding the parasitological fauna of cetaceans is crucial for both their health and conservation efforts. This study presents the first findings on the parasitological findings of harbour porpoises from the Turkish coast of the western Black Sea and explores the association between stomach contents, parasitological findings, and body length.

Key words: Anisakidea, *Contracaecum* spp., harbour porpoises, *Hysterothylacium* spp., western Black Sea, stomach content

1. Introduction

The Black Sea is home to a variety of cetaceans, including bottlenose dolphin *Tursiops truncatus* (Montagu, 1821), the common dolphin (*Delphinus delphis* Linnaeus, 1758), and the harbour porpoise *Phocoena phocoena* (Linnaeus, 1758). Harbour porpoises are small cetaceans inhabiting temperate to subpolar waters of the Northern Hemisphere, including the North Atlantic, North Pacific, and Black Sea, primarily in coastal and continental shelf waters. Their conservation status is classified as 'Least Concern' by International Union for Conservation of Nature and Natural Resources Red List of Threatened Species [1]. However, the subspecies of harbour porpoise found exclusively in the Black Sea, Azov Sea, Turkish Straits System, and the northern Aegean Sea is known as the Black Sea harbour porpoise (*Phocoena phocoena relicta* Abel, 1905). This population is classified as Endangered due to its small and isolated nature [2–4].

Bycatch, overfishing (possibly in combination with climate change), chemical pollution (including urban and agricultural runoff, industrial effluents, shipping

accidents), poor solid waste management, diseases (mostly morbillivirus), coastal infrastructure, pile driving, and high-density vessel traffic are the main threats, affecting the population size of this subspecies [2, 4]. However, the most serious threat to Black Sea harbour porpoises, is bycatch [5–7]. Additionally, bacteriological, virological, and parasitological agents—including nematodes—can cause significant diseases, especially when combined with other factors such as habitat degradation, comorbid diseases, immunotoxins, or other stressors (nutritional, environmental, or human-interactions) [8]. Although parasites can be opportunistically benign, they can have a significant impact on populations. While this impact is unlikely in large populations, it can pose a challenge in small, isolated populations [8].

Pholeter gastrophylus (Kossack, 1910) Odhner, 1914, *Diphyllobothrium stemmecephalum* Cobbold, 1858, *D. latum* (Linnaeus, 1758) Lühe, 1910, and *Anisakis simplex* (Rudolphi, 1809) Dujardin, 1845 were previously reported in the gastrointestinal system of Black Sea harbour porpoises from the northern Black Sea between 1935

* Correspondence: erdemdanyer@gmail.com

and 1994 [9]. However, only *A. simplex* (Rudolphi, 1809) Dujardin, 1845 has been identified as a natural mortality factor in the gastrointestinal system of Black Sea cetaceans [10]. *Halocercus* spp. [11] and *Stenurus minor* (Kühn, 1829) Baylis & Daubney, 1925 [12] have been detected in the lungs of harbour porpoises from the southern Black Sea. Pekmezci et al. [12] also reported that Anisakid, pseudaliid, filarioid, and spirurids nematodes were absent in harbour porpoises and bottlenose dolphins from the Black Sea.

Parasitic nematodes of the Anisakidae Railliet & Henry, 1912 (genera: *Anisakis* Dujardin, 1845; *Pseudoterranova* Mozgovoi, 1951; *Contracaecum* Railliet & Henry, 1912), have an aquatic, primarily marine lifecycle. Their definitive hosts include marine mammals and piscivorous birds, while crustaceans, cephalopods, and fish are their intermediate or paratenic hosts globally [8, 13–15]. The Anisakidae Railliet & Henry, 1912 is probably the most successful in terms of host colonization potential and is found in the gastrointestinal system of marine mammals [16–18]. *Anisakis* spp. are commonly found in the first chamber of a cetacean's stomach, while *Pseudoterranova* spp. and *Contracaecum* spp. are found in the second chamber [8, 18]. In marine mammals, these parasites can cause stomach wall ulceration and lesions, mechanical obstructions, gastric ulcers, volcano type wounds, inflammation, fibrosis, and other gastrointestinal disorders [8,19–22].

Understanding marine mammal ecology and health, along with preparing for possible rehabilitation initiatives, necessitates an understanding of parasitological fauna. For the objectives of preventative medicine and rehabilitation, scientists must have a thorough knowledge of the local parasitic fauna and host interactions.

The aim of this study is to present the parasitological findings of harbour porpoises from the Turkish coasts of the western Black Sea to date and to evaluate the relationship between stomach content, parasitological findings, and body length.

2. Materials and methods

The study was designed as a cross-sectional study using nonrandomized sampling methods. Nematode parts (n = 450) were opportunistically collected from the stomach contents of 42 harbour porpoises (33 females, 9 males), which were bycaught (n = 40 in turbot nets) and stranded (n = 2) between April and June of 2002 and 2003 on the western Black Sea coast of Türkiye [5,23]. Detailed information on the bycatch location and date, individual sex, body length, and stomach contents can be found in previous studies [5,6]. Prior to analysis, all stomachs were stored at -20 °C. The stomachs were thawed before the examination. The stomach contents were then mechanically removed,

washed with tap water, sieved through a 200 µm mesh sieve, and stored at room temperature in 70% ethanol [23]. During stomach content analyses, macroparasites were collected and stored in 70% ethanol at room temperature.

Nematodes were examined under a stereomicroscope and classified based on their lengths. They were cleaned in saline using a pipette and fine brushes. The nematodes were stored at room temperature in a 70% ethanol and %5 glycerol solution and transparentized with lactophenol solution for examination [24]. The nematodes were morphologically identified under a light microscope at 10–40× magnification.

The cranial and caudal structure, lips, connection between the oesophagus and ventriculus, cecum, and position of the excretory pore of nematodes were examined morphologically. The following measurements were taken: total length, lips, nerve ring to cranial end, oesophagus, ventriculus, cecum, anus to tail, mucron, and spicules. The nematodes' specific parts were photographed and archived. The parasite was identified in accordance with the relevant literature [13,25–28].

The body length of harbour porpoises, the amount of parasites collected from each stomach, and the data on stomach contents (determined by the number of fish otolith individual) were evaluated using the Spearman correlation test due to the nonparametric distribution of the variables, as assessed through both visual and analytical methods. For all analyses, statistical significance was set at $p < 0.05$. The data were analysed using IBM SPSS (V. 21, Armonk, NY, USA) software.

3. Results

In this study, 450 nematode parts were collected from 33 of the 42 harbour porpoises (78.5%), of which 232 were intact. The intact parasites consisted of 73.2% *Hysterothylacium* spp. (16 males, 80 females, and 85 third-stage larvae) and 20.8% *Contracaecum* spp. (8 males, 21 females, 22 third-stage larvae). The body length of the harbour porpoises showed a moderate correlation ($r = 0.39$, $p = 0.01$), while the amount of *Sprattus sprattus* (Linnaeus, 1758) exhibited a medium correlation ($r=0.42$, $p=0.006$) with the number of parasites collected from the stomachs (Table).

Morphological findings of *Hysterothylacium* spp: The parasite's body length was 35.19 mm, with a maximum diameter of 683 µm. The excretory pore was located at the nerve ring (Figure 1). The intestinal appendix measured 284.68 µm in length, while the distance from the intestinal appendix to the posterior end ranged from 285.60 to 295.80 µm. The cranial end to excretory canal distance was 510 µm. The rectal glandular cells were prominent. The conical tail was 9.03 µm long. The average egg diameter was 54.34 µm (Figure 2). The third-stage larva measured 9.94 mm in length, with a width of 160.5–207.0 µm at the

Table. Sex, body length (cm), number of collected parasites and number of *S. sprattus* information of the harbour porpoises.

No.	ID no.	Sex	Length (cm)	Number of collected parasites	Number of <i>S. sprattus otoliths</i>
1	02001	Female	120	27	10
2	02002	Female	107	0	0
3	02003	Female	115	3	10
4	02004	Female	124	0	0
5	02005	Male	119	8	48
6	02006	Female	113	11	85
7	02007	Male	105	5	4
8	02008	Female	124	1	13
9	02009	Male	101	0	0
10	02010	Male	103	1	0
11	02011	Male	121	1	4
12	02012	Female	118	1	0
13	02013	Female	113	0	1
14	03004	Female	135	0	0
15	03005	Female	104	9	0
16	03006	Female	128	15	0
17	03009	Female	119	0	176
18	03010	Female	117	12	14
19	03011	Female	139	4	0
20	03012	Male	103	0	0
21	03023	Female	128	12	15
22	03024	Female	127	21	95
23	03025	Female	131	7	126
24	03026	Male	98	1	0
25	03027	Female	128	74	256
26	03028	Female	129	8	0
27	03032	Female	130	32	26
28	03033	Female	134	53	38
29	03034	Female	140	23	116
30	03035	Female	135	1	16
31	03044	Female	130	33	0
32	03045	Female	120	9	11
33	03046	Female	136	31	8
34	03047	Female	135	0	29
35	03048	Male	119	0	8
36	03049	Female	136	18	52
37	03050	Female	129	23	52
38	03051	Female	129	6	16
39	03052	Male	122	4	0
40	03053	Female	121	17	2
41	03054	Female	125	8	6
42	03055	Female	134	2	4



Figure 1. *Hysterothylacium* sp. a) Nerve ring, with square indicating the excretory pore; b) excretory pore (40× magnification); c) caudal end of *Hysterothylacium* sp.

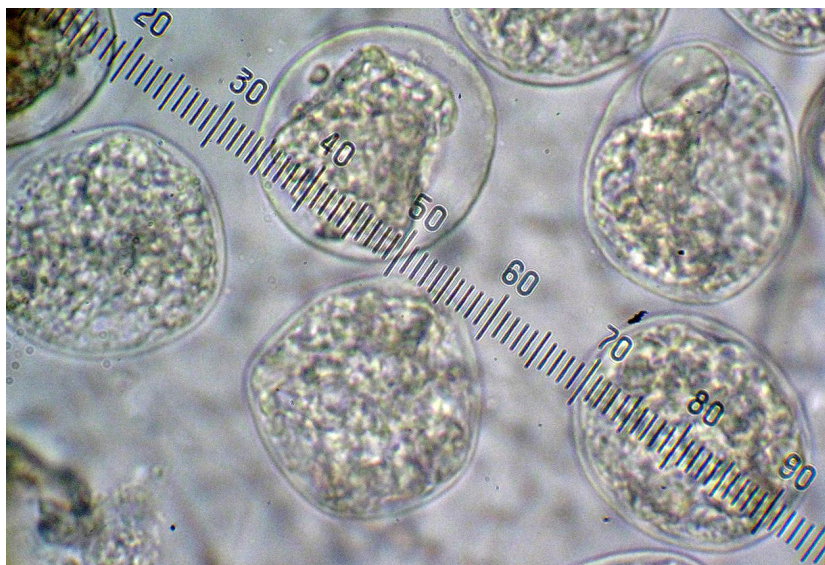

Figure 2. *Hysterothylacium* sp. eggs (40× magnification).

nerve ring level. The excretory canal of the third-stage larva was 396.0 µm, the intestinal appendix was 210 µm long, and the spine tail was 18 µm long.

Morphological findings of *Contracaecum* spp.: The male genital appendix measured 255 µm in length, while the spiculum length ranged from 582.3 to 612 µm. In females, the distance from the intestinal appendix to the posterior end was 193.8 µm. The excretory pore was located at the cranial end (Figure 3). Figure 3 also shows the positions of the intestines, ventriculus, intestinal cecum, and oesophagus.

The two nematode species were morphologically distinguished based on the location of the excretory pore, as described in previous literature [29]. In *Hysterothylacium* spp., the excretory pore is located at or near the level of the nerve ring, whereas in *Contracaecum* spp., it is positioned at the anterior end, near the base of the lips.

4. Discussion

Although parasites are not the primary cause of mortality in wild animals, they remain a major focus of research in wildlife diseases. Due to their ease of preservation and

storage, parasites can be opportunistically collected from decomposed animals. In our case, the materials were collected opportunistically and stored during a previous stomach content study [23]. Data on individuals' body length, sex, and sample collection were also reported by Tonay [5]. These sample collection efforts contribute to tissue banks and museum collections, facilitating further collaboration among scientists.

Different *Hysterothylacium* spp. have been reported in various fish species from the Black Sea. *H. aduncum* (Rudolphi, 1802) Deardorff & Overstreet, 1981 has been recorded in *Merlangius merlangus euxinus* (von Nordmann, 1840) [30–34]; *Mullus barbatus* Linnaeus, 1758 [34]; *Trachurus trachurus* (Linnaeus, 1758) [32]; *Sprattus sprattus* (Linnaeus, 1758) [33, 35]; *Mullus barbatus ponticus* Essipov, 1927 [36]; *Trachurus mediterraneus* (Steindachner, 1868), *Engraulis encrasicolus* (Linnaeus, 1758), *Belone belone* (Linnaeus, 1760), *Caspialosa* spp., *Sciaena umbra* Linnaeus, 1758, *Scorpaena porcus* Linnaeus, 1758, *Liza aurata* (Risso, 1810), *Spicara smaris* (Linnaeus, 1758), *Gobius niger* Linnaeus, 1758, *Sarda sarda* (Bloch, 1793), and *Uranoscopus scaber* Linnaeus, 1758

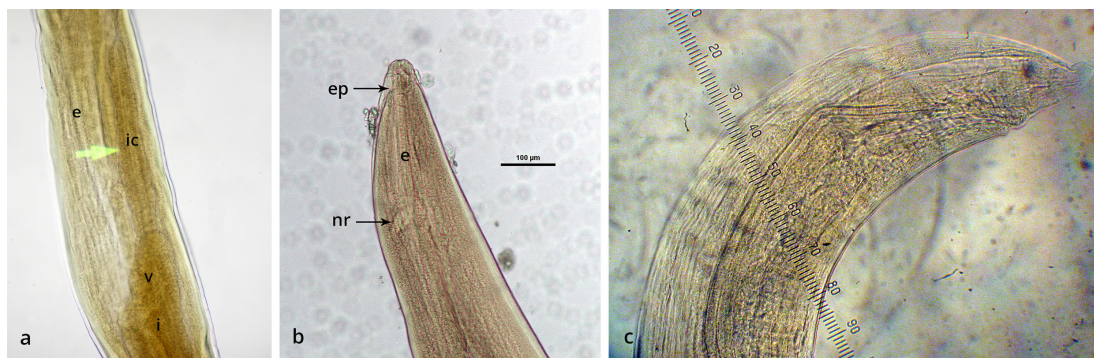


Figure 3. *Contracaecum* sp. a) e: oesophagus, ic: intestinal caecum, v: ventriculus, i: intestinalis (40× magnification); b) ep: excretory pore; e: oesophagus; nr: nerve ring. Bar: 100 µm; c) caudal end of a male individual (40× magnification).

[34]. *H. fabri* (Rudolphi, 1819) Dearnorff & Overstreet, 1980 has been reported in red mullet (*Mullus barbatus ponticus* Essipov, 1927) [36]. The stomach contents of the hosts from which the parasites were collected included sprat, whiting, gobies, anchovy, and red mullet [23]. *Hysterothylacium* spp. may be present incidentally, despite the harbour porpoise not being part of the parasite's life cycle. The incidental presence of *Hysterothylacium* spp. has been previously reported, supporting the finding of this study [37–39].

Contracaecum spp. was the other major parasite identified in this study. *Contracaecum* spp. have been found in red mullet (*Mullus barbatus ponticus* Essipov, 1927) [36], while *C. overstreeti* Mattiucci, Paoletti, Solorzano & Nascetti, 2010 has been recorded in *Mugil cephalus* Linnaeus, 1758 [40]. *C. microcephalum* (Rudolphi, 1809) Baylis, 1920 has been reported in gobiid fishes (Actinopterygii: Gobiidae Cuvier, 1816) from the northern and northwestern Black Sea [41, 42]. *Contracaecum* spp., *C. aduncum* (Rudolphi, 1802), *Porrocaecum* spp., *Anisakis* spp. have been detected in sprat, anchovy, horse mackerel along the Romanian coast [43]; *C. aduncum* (Rudolphi, 1802) has been reported in anchovies *Engraulis encrasicolus* (Linnaeus, 1758) a prevalence of up to 70% in the Black Sea [44]. *C. multipapillatum* (Drasche, 1882) Lucker, 1941 has been genetically confirmed in golden grey mullet (*Chelon auratus* (Risso, 1810) from the Crimean Peninsula [45]. The third-stage larva of *C. rudolphii* (Hartwich, 1964) has been genetically confirmed in *Neogobius melanostomus* (Pallas, 1814) [28]. *Contracaecum* spp. and *C. aduncum* (Rudolphi, 1802) have been previously reported in harbour porpoises from the waters of Canada, Scotland, Poland, British Columbia, Iceland, Denmark, Norway, and Germany [16,46–49]. In the present study, 20.8% of the total parasites were identified as *Contracaecum* spp. This result aligns with a previous study that reported *Contracaecum* spp. in 20% of 37 harbour porpoises [49]. The presence of *Contracaecum* spp. in this study may be

linked to the widespread occurrence of these nematodes in Phocidae, which serve as alternative final hosts, as noted by Dzido et al. [49] for *C. osculatum* (Rudolphi, 1802) Baylis, 1920.

Most cetaceans become infected by consuming fish or squid. Once the nematodes mature into adults, they mate in the cetacean's stomach, completing the cycle when the female nematode releases fertilized eggs [50]. The correlation between sprat abundance and parasite load appears normal, as sprat is likely a primary transmission host for nematodes. Body length is clearly associated with the amount of prey consumed. Increased prey consumption evidently raises the likelihood of nematode transfer. In support of our findings, Nadolna-Alytn et al. [51] proposed that sprat may act as a transmitter of *C. osculatum* (Rudolphi, 1802) Baylis, 1920 to piscivorous organisms in several regions of the Baltic Sea. A previous study concluded that *C. turgidum* infection in 282 Hawaiian monk seals (*Monachus schauinslandi* Matschie, 1905) was not related to morphometric measurements [52]. Mateu et al. [53] examined the intestinal helminths of 52 striped dolphins *Stenella coeruleoalba* (Meyen, 1833) and investigated their association with host sex, body length, and age. They found no association, likely due to the high degree of decomposition. Additionally, in harbour porpoises, increasing body length increased the likelihood of stomach parasite presence [54]. According to the reviewed literature, stomach parasites are likely associated with body length; however, this relationship may vary if the entire gastrointestinal system was examined. Further data on parasitological findings, morphometric measurements, and stomach content analysis are required to support this remark.

Anisakis spp. have been detected in sprat, anchovy, horse mackerel along the Romanian coast [43], while *Anisakis pegreffii* Campana-Rouget & Biocca, 1955 has been found in *Trachurus mediterraneus* (Steindachner, 1868) along the Turkish Black Sea coast [34]. However,

no zoonotic *Anisakis* species were detected in 1025 commercially available fish mainly *Engraulis encrasicolus* (Linnaeus, 1758) and *Trachurus trachurus* Linnaeus, 1758) belonging to 16 different species from the Middle and Eastern Black Sea [55]. Furthermore, *Anisakis* spp. were not reported in Öktener's checklists [56, 57]. In this study, *Anisakis* spp. were not detected, consistent with Öktener's checklist.

At least 20 fish specimens were identified in the stomachs of Black Sea harbour porpoises, with three constituting the primary prey: anchovy *Engraulis encrasicolus* (Linnaeus, 1758), sprat *Sprattus sprattus phalericus* (Risso, 1827), and whiting *Merlangius merlangus* (Linnaeus, 1758) [23,58,59]. The stomach contents examined in this study contained seven fish species (sprat, whiting, sole (*Solea* spp.), gobies *Gobiidae* spp.), European hake (*Merluccius merluccius* (Linnaeus, 1758), anchovy *Engraulis encrasicolus* (Linnaeus, 1758) and red mullet (*Mullus barbatus* Linnaeus, 1758), and 26 crustacean individuals (*Crangonidae* spp., *Decapoda* spp., *Crustacea* spp., *Caridae* spp.) species were reported [23]. No prior findings of gastrointestinal parasites in cetaceans from the Turkish coasts of the Black Sea have been reported. Therefore, to contextualize our findings, we reviewed previous parasitology studies on their prey species.

There are some limitations to this study. Due to the sampling method, the results should not be interpreted as prevalence estimates or generalized to the entire population. We were unable to perform genomic analysis since the majority of the parasites had shrunk due to storage conditions and transparentized in lactophenol.

In addition, sharing these findings with the scientific community is important as it provides one of the first data on harbour porpoise parasites from the western Black Sea region. Future parasitological studies will be essential for obtaining updated information.

5. Conclusion

As demonstrated in this study, collecting diverse samples can serve as a primary resource for future research. Wildlife sample collection is inherently challenging, and it is strongly recommended to collect samples promptly from all cases to facilitate further research. This study serves as an example of effective marine mammal sampling practices considering the available field conditions. Findings of this study reveal the presence of the zoonotic nematodes in the cetaceans from the western Black Sea. Understanding the distribution of Anisakidae Railliet & Henry, 1912 in marine mammals will help evaluate their diet and habitat preferences while also assessing zoonotic risks in coastal environments.

Acknowledgments

We would like to thank to Prof. Dr Aydın Gürel and Prof. Dr Funda Yıldırım for taking the photographs of the nematodes, Prof. Dr Bayram Öztürk, Prof. Mercedes Fernández, Dr Dan Morricks, Dr Sergey Krivokhizhin, and Dr Alexei Birkun for sharing their valuable knowledge, and Dr. Ufuk Erol for his comments on this paper.

Conflict of interest

The authors declare no potential conflicts of interest.

References

1. Braulik GT, Minton G, Amano M, Bjørge, A. *Phocoena phocoena* (amended version of 2020 assessment). The IUCN (International Union for Conservation of Nature and Natural Resources) Red List of Threatened Species 2023; e.T17027A247632759. <https://doi.org/10.2305/IUCN.UK.2023-1.RLTS.T17027A247632759.en>
2. Birkun Jr AA, Frantzis A. *Phocoena phocoena* ssp. *relicta*. IUCN (International Union for Conservation of Nature and Natural Resources) Red List Threat Species 2008; e.T17030A6737111. <https://doi.org/10.2305/IUCN.UK.2008.RLTS.T17030A6737111.en>
3. Viaud-Martínez KAKA, Vergara MMMM, Gol'din PE, Ridoux V, Öztürk AA et al. Morphological and genetic differentiation of the Black Sea harbour porpoise *Phocoena phocoena*. Marine Ecology Progress Series 2007; 338: 281-294. <https://doi.org/10.3354/meps338281>
4. Notarbartolo di Sciara G, Tonay AM. Conserving whales, dolphins and porpoises in the Mediterranean Sea, Black Sea and adjacent Areas: An ACCOBAMS (The Agreement on the Conservation of Cetaceans of the Black Sea, Mediterranean Sea and contiguous Atlantic area) Status Report. Monaco: ACCOBAMS (The Agreement on the Conservation of Cetaceans of the Black Sea, Mediterranean Sea and contiguous Atlantic area); 2021.
5. Tonay AM, Öztürk B. Cetacean bycatches in turbot fishery on the western coast of the Turkish Black Sea. In: Proceedings of International Symposium Fish Zoology in Memory of Ord. Prof. Dr Curt Kossig for his 100th birth Anniversary 2003; (October): 23-26.
6. Tonay AM. Estimates of cetacean by-catch in the turbot fishery on the Turkish Western Black Sea Coast in 2007 and 2008. Journal of the Marine Biological Association of the United Kingdom 2016; 96 (4): 993-998. <https://doi.org/10.1017/S0025315416000060>

7. Popov D, Meshkova G, Vishnyakova K, Ivanchikova J, Paiu M et al. Assessment of the bycatch level for the Black Sea harbour porpoise in the light of new data on population abundance. *Frontiers in Marine Science* 2023; 10: 1119983. <https://doi.org/10.3389/fmars.2023.1119983>
8. Measures LN. Helminths and parasitic arthropods. In: Gulland FMD, Dierauf LA, Whitman KL (editors). *CRC Handbook of Marine Mammal Medicine*. 3rd ed. Boca Raton, FL, USA: CRC Press; 2018. pp. 471-497.
9. Birkun AJ, Krivokhizhin SV. Present and causes of the Black Sea cetacean population suppression. Communication I. Population dynamics, abiotic and biotic limiting factors. *Vestnik Zoologii* 1996; 30 (3): 36-42.
10. Jr Birkun A. Natural mortality factors affecting cetaceans in the Black Sea. In: Notarbartolo di Sciarra G (Editor). *Cetaceans of the Mediterranean and Black Seas: state of knowledge and conservation strategies. A Report to the ACCOBAMS (The Agreement on the Conservation of Cetaceans of the Black Sea, Mediterranean Sea and contiguous Atlantic area) Secretariat. Section 16. Monaco: ACCOBAMS (The Agreement on the Conservation of Cetaceans of the Black Sea, Mediterranean Sea and contiguous Atlantic area); 2002. pp. 1-13.*
11. Veryeri NG. Postmortem examinations of stranded dolphins found on the Black Sea coast near Ordu, Turkey (Mammalia: Cetacea). *Zoology in the Middle East* 2012; 55 (1): 129-132. <https://doi.org/10.1080/09397140.2012.10648928>
12. Pekmezci GZ, Yardimci B, Gürler AT, Bölükbaş CS, Açıci M et al. Survey on the presence of nematodes and associated with pathology in marine mammals from Turkish Waters. *Journal of Kafkas University Veterinary Faculty* 2013; 19 (6): 1035-1038. <https://doi.org/10.9775/kvfd.2013.9409>
13. Adroher-Auroux FJ, Benítez-Rodríguez R. Anisakiasis and Anisakis: an underdiagnosed emerging disease and its main etiological agents. *Research in Veterinary Science* 2020; 132: 535-545. <https://doi.org/10.1016/j.rvsc.2020.08.003>
14. Mattiucci S, Paoletti M, Solorzano AC, Nascetti G. *Contracaecum gibsoni* and *C. overstreeti* (Nematoda: Anisakidae) from the Dalmatian pelican *Pelecanus crispus* (L.) in Greek waters: genetic and morphological evidence. *Systemic Parasitology* 2010; 75: 207-224. <https://doi.org/10.1007/s11230-009-9220-8>
15. Felix JR. *Reported Incidences of Parasitic Infections in Marine Mammals from 1892 to 1978*. Lincoln, NE, USA: Zea Books; 2013.
16. Smith JW. Ulcers associated with larval *Anisakis simplex* (Nematoda: Ascaridoidea) in the forestomach of harbour porpoises *Phocoena phocoena* (L.). *Canadian Journal of Zoology* 1989; 67 (9): 2270-2276. <https://doi.org/10.1139/z89-319>
17. Abollo E, Lopez A, Gestal C, Benavente P, Pascual S. Long-term recording of gastric ulcers in cetaceans stranded on the Galician (NW Spain) coast. *Diseases of Aquatic Organisms* 1998; 32 (1): 71-73. <https://doi.org/10.3354/dao032071>
18. Raga JA, Fernández M, Balbuena JA, Aznar FJ. Parasites. In: Perrin WF, Würsig B, Thewissen JGM (editors). *Encyclopedia of Marine Mammals*. 2nd ed. Canada: Academic Press; 2009. pp. 821-830. <https://doi.org/10.1016/B978-0-12-373553-9.00193-0>
19. Abollo E, Gestal C, López A, González AF, Guerra A et al. Squid as trophic bridges for parasite flow within marine ecosystems: The case of *Anisakis simplex* (Nematoda: Anisakidae), or when the wrong way can be right. *South African Journal of Marine Science Cephalopod Biodiversity, Ecology and Evolution* 1998; 223-232. <https://doi.org/10.2989/025776198784126575>
20. Jaber JR, Pérez J, Arbelo M, Zafra R, Fernández A. Pathological and immunohistochemical study of gastrointestinal lesions in dolphins stranded in the Canary Island. *Veterinary Record* 2006; 159 (13): 410-414. <https://doi.org/10.1136/vr.159.13.410>
21. Dailey M, Stroud R. Parasites and associated pathology observed in cetaceans stranded along the Oregon coast. *Journal of Wildlife Diseases* 1978; 14 (4): 503-511. <https://doi.org/10.7589/0090-3558-14.4.503>
22. Duignan P. Aquatic Mammals. In: Urdes L, Walster C, Tepper J (editors). *Pathology and Epidemiology of Aquatic Animal Diseases for Practitioners*. Wiley-Blackwell; 2023: 224-350. <https://doi.org/10.1002/9781119839729>
23. Tonay AM, Dede A, Öztürk AA, Öztürk B. Stomach content of Harbour Porpoises (*Phocoena phocoena*) from The Turkish Western Black Sea in spring and early summer. *Rapports et procès-verbaux des réunions de la Commission Internationale pour l'Exploration Scientifique de la Mer Méditerranée* 2007; 38: 616.
24. Berland B. Nematodes from some Norwegian marine fishes. *Sarsia* 1961; 2 (1): 1-50. <https://doi.org/10.1080/00364827.1961.10410245>
25. Delyamure SL. *The helminth fauna of marine mammals in the light of their ecology and phylogeny*. Washington DC, USA: Department of the Navy; 1968.
26. Dailey MD. Parasitic diseases. In: Dierauf LA, Gulland FMD (editors). *CRC Handbook of Marine Mammal Medicine*. 2nd ed. Boca Raton, FL, USA: CRC Press; 2001: pp. 357-379. <https://doi.org/10.1201/9781420041637>
27. Bicudo AJA, Tavares LER, Luque JL. Anisakidae larvae (Nematoda: Ascaridoidea) parasites of the bluewing searobin *Prionotus punctatus* (Bloch, 1793) (Osteichthyes: Triglidae) from the coastal zone of the State of Rio de Janeiro. *Revista Brasileira de Parasitologia Veterinária* 2005; 14 (3): 109-118.
28. Pronkina NV, Spiridonov SE. Third-stage juveniles of *Contracaecum* sp. (Anisakidae, Ascaridomorpha) from the round goby *Neogobius melanostomus* of the Black Sea. *Russian Journal of Nematology* 2020; 28 (1): 45-52. <https://doi.org/10.24411/0869-6918-2020-10004>
29. Deardorff TL, Overstreet RM. Larval *Hysterothylacium* (=Thynnascaris) (Nematoda: Anisakidae) from fishes and invertebrates in the Gulf of Mexico. *Proceedings of the Helminthological Society of Washington* 1981; 48 (2): 113-126.

30. Ismen A, Bingel F. Nematode infection in the whiting *Merlangius merlangus euxinus* off Turkish Coast of the Black Sea. *Fisheries Research* 1999; 42 (1-2): 183-189. [https://doi.org/10.1016/S0165-7836\(99\)00022-3](https://doi.org/10.1016/S0165-7836(99)00022-3)
31. Özer A, Kornychuk YM, Yurakhno V, Öztürk T. Seasonality and host-parasite interrelationship of *Hysterothylacium aduncum* (Nematoda) in whiting *Merlangius merlangus* off the southern and northern coasts of the Black Sea. *Helminthology* 2016; 5 3(3): 248-256. <https://doi.org/10.1515/helmin-2016-0025>
32. Pekmezci GZ, Bolukbas CS, Gurler AT, Onuk EE. Occurrence and molecular characterization of *Hysterothylacium aduncum* (Nematoda: Anisakidae) from *Merlangius merlangus euxinus* and *Trachurus trachurus* off the Turkish coast of Black Sea. *Parasitology Research* 2012; 112 (3): 1031-1037. <https://doi.org/10.1007/s00436-012-3227-9>
33. Telli F, Doran F. Pathologic abnormalities of fish in Turkish Coastal Waters of the Eastern Black Sea. *Turkish Journal of Zoology* 1997; 21 (1): 85-90.
34. Tepe Y, Oğuz MC. Nematode and acanthocephalan parasites of marine fish of the eastern Black Sea coasts of Turkey. *Turkish Journal of Zoology* 2013; 37 (6): 753-760. <https://doi.org/10.3906/zoo-1206-18>
35. Avsar D. Parasitic fauna of sprat (*Sprattus sprattus phalericus* RISSO, 1826) from the Turkish Black Sea coast. *Acta Adriatica* 1997; 38 (1): 71-76.
36. Ozturk T, Yesil A. Metazoan Parasite Fauna of the Red Mullet, *Mullus barbatus ponticus* Essipov, 1927 in the Sinop Coasts of the Black Sea. *Turkish Journal of Fisheries and Aquatic Sciences* 2018; 18: 123-160. <https://doi.org/10.4194/1303-2712-v18>
37. Lakemeyer J, Siebert U, Abdulmawjood A, Ryeng KA, IJsseldijk LL et al. Anisakid nematode species identification in harbour porpoises (*Phocoena phocoena*) from the North Sea, Baltic Sea and North Atlantic using RFLP analysis. *International Journal for Parasitology: Parasites and Wildlife* 2020; 12: 93-98. <https://doi.org/10.1016/j.ijppaw.2020.05.004>
38. Ryeng KA, Lakemeyer J, Roller M, Wohlsein P, Siebert U. Pathological findings in bycaught harbour porpoises (*Phocoena phocoena*) from the coast of Northern Norway. *Polar Biology* 2022; 45 (1): 45-57. <https://doi.org/10.1007/s00300-021-02970-w>
39. Herreras MV, Kaarstad SE, Antonio Balbuena J, Kinze CC, Antonio Raga J. Helminth parasites of the digestive tract of the harbour porpoise *Phocoena phocoena* in Danish waters: a comparative geographical analysis. *Diseases of Aquatic Organisms* 1997; 28 (3): 163-167. <https://doi.org/10.3354/dao028163>
40. Pekmezci GZ, Yardimci B. On the occurrence and molecular identification of *Contracaecum* larvae (Nematoda: Anisakidae) in *Mugil cephalus* from Turkish waters. *Parasitology Research* 2019; 118: 1393-1402. <https://doi.org/10.1007/s00436-019-06278-x>
41. Kvach Y. Helminths of the marbled goby (*Pomatoschistus Marmoratus*) a Mediterranean immigrant in the Black Sea fauna. *Vestnik Zoologii* 2010; 44 (6): 509-518. <https://doi.org/10.2478/v10058-010-0034-6>
42. Kvach Y. A comparative analysis of helminth faunas and infection parameters of ten species of gobiid fishes (Actinopterygii: Gobiidae) from the North-Western Black Sea. *Acta Ichthyologica et Piscatoria* 2005; 35 (2): 103-110. <https://doi.org/10.3750/AIP2005.35.2.06>
43. Totoiu A, Patriche N. Evaluation of the parasitic degree and the effects caused on the commercial fish stocks at the Romanian Black Sea coast. *Proceedings of the Sixth Scientific Conference of Doctoral Schools from "Dunarea de Jos" University of Galati* 2018; 41 (1): 48-56. <https://doi.org/10.35219/ann-ugal-math-phys-mec.2018.1.07>
44. Tuncel VA, Akmirza A. The Comparison of the endoparasites of anchovies *Engraulis encrasicolus* (Linnaeus, 1758) live in the sea of the Marmara and the Black Sea. *Journal of Fisheries and Aquatic Science* 2006; 20: 17-26.
45. Pronkina NV, Spiridonov SE. Morphological and molecular characterisation of anisakid juveniles from the golden grey mullet of the Black Sea. *Russian Journal of Nematology* 2018; 26 (1): 87-92. <https://doi.org/10.24411/0869-6918-2018-10008>
46. Siebert U, Tolley K, Vikingsson GA, Ólafsdóttir D, Lenhert K et al. Pathological findings in harbour porpoises (*Phocoena phocoena*) from Norwegian and Icelandic waters. *Journal of Comparative Pathology* 2006; 134 (2-3): 134-142. <https://doi.org/10.1016/j.jcpa.2005.09.002>
47. Fenton H, Daoust PY, Forzán MJ, Vanderstichel RV, Ford JKB et al. Causes of mortality of harbor porpoises *Phocoena phocoena* along the Atlantic and Pacific coasts of Canada. *Diseases of Aquatic Organisms* 2017; 122 (3): 171-183. <https://doi.org/10.3354/dao03080>
48. Siebert U, Pawliczka I, Benke H, Vietinghoff V von, Wolf P et al. Health assessment of harbour porpoises (*Phocoena phocoena*) from Baltic area of Denmark, Germany, Poland and Latvia. *Environment International* 2020; 143 (December 2019): 105904 Contents. <https://doi.org/10.1016/j.envint.2020.105904>
49. Dzido J, Rolbiecki L, Izdebska JN, Rokicki J, Kuczkowski T et al. A global checklist of the parasites of the harbor porpoise *Phocoena phocoena*, a critically-endangered species, including new findings from the Baltic Sea. *International Journal for Parasitology: Parasites and Wildlife* 2021; 15: 290-302. <https://doi.org/10.1016/j.ijppaw.2021.07.002>
50. Dailey MD. Parasites of marine mammals. In: Rohde K (editor). *Marine Parasitology*. Collingwood, VIC, Australia: CSIRO Publishing; 2005. pp. 408-414. <https://doi.org/10.5860/choice.43-5289>
51. Nadolna-Ałtyn K, Szostakowska B, Podolska M. Sprat (*Sprattus sprattus*) as a possible source of invasion of marine predators with *Contracaecum osculatum* in the Southern Baltic Sea. *Russian Journal of Marine Biology* 2018; 44 (6): 471-476. <https://doi.org/10.1134/S1063074018060093>
52. Reif JS, Kliks MM, Aguirre AA, Borjesson DL, Kashinsky L et al. Gastrointestinal helminths in the Hawaiian Monk Seal (*Monachus schauinslandi*): Associations with body size, hematology, and serum chemistry. *Aquatic Mammals* 2006; 32 (2): 157-167. <https://doi.org/10.1578/am.32.2.2006.157>

53. Mateu P, Raga JA, Fernández M, Aznar FJ. Intestinal helminth fauna of striped dolphins (*Stenella coeruleoalba*) in the western Mediterranean: No effects of host body length, age and sex. *Marine Mammal Science* 2014; 30 (3): 961-977. <https://doi.org/10.1111/mms.12096>
54. ten Doeschate MTI, Ijsseldijk LL, Hiemstra S, Jong EA, Strijkstra A et al. Quantifying parasite presence in relation to biological parameters of harbour porpoises *Phocoena phocoena* stranded on the Dutch coast. *Diseases of Aquatic Organisms* 2017; 127 (1): 49-56. <https://doi.org/10.3354/dao03182>
55. Pekmezci GZ, Onuk EE, Bolukbas CS, Yardimci B, Gurler AT et al. Molecular identification of Anisakis species (Nematoda: Anisakidae) from marine fishes collected in Turkish waters. *Veterinary Parasitology* 2014; 201 (1-2): 82-94. <https://doi.org/10.1016/j.vetpar.2014.01.005>
56. Öktener A. An updated checklist of parasitic helminths of marine fish from Turkey. *Transylvanian Review of Systematical and Ecological Research* 2014; 16 (2): 55-96. <https://doi.org/10.1515/trser-2015-0017>
57. Öktener A. A checklist of parasitic helminths reported from sixty-five species of marine fish from Turkey including two new records of monogeneans. *Zootaxa* 2005; (1063): 33-52. <https://doi.org/10.11646/zootaxa.1063.1.2>
58. Krivokhizhin SV, Birkun AA. Preferable diet of harbour porpoises (*Phocoena phocoena relicta*) in the northern and western Black Sea. In: *Proceedings of the 23rd Annual Conference European Cetacean Society; İstanbul, Türkiye; 2009*. pp. 128-129.
59. Bilgin S, Onay H, Köse O, Yeşilçiçek T. About stranding and accidentally caught cetaceans in the Black Sea: death reasons, feeding characteristics and pregnancy. *Turkish Journal of Agricultural and Natural Sciences* 2018; 5 (4): 447-454.